

The choice of surgical correction method depending on the etiology of decompensated chronic venous insufficiency

V. I. Rusyn^{1,A}, F. M. Pavuk^{1,C,D}, V. V. Rusyn^{1,B,E}, M. I. Borsenko^{2,F,E}

¹State University "Uzhhorod National University", Ukraine, ²Transcarpathian Regional Clinical Hospital named after A. Novak, Uzhhorod, Ukraine

A – research concept and design; B – collection and/or assembly of data; C – data analysis and interpretation; D – writing the article; E – critical revision of the article; F – final approval of the article

Keywords:

trophic ulcer, varicose veins, post-thrombotic syndrome, phlebectomy, crossectomy.

Ключові слова:

трофічна виразка, варикозна хвороба, посттромботичний синдром, флебектомія, кроссектомія.

Надійшла до редакції / Received: 13.10.2023

Після доопрацювання / Revised: 28.11.2023

Схвалено до друку / Accepted: 30.11.2023

Конфлікт інтересів:
відсутній.

Conflicts of interest:
authors have no conflict of interest to declare.

***E-mail:**
fedjapavuk111@gmail.com

Aim. To evaluate the immediate and distant results of treatment depending on the etiology of chronic venous insufficiency in the stage of decompensation.

Materials and methods. This work presents an analysis of the results of treatment of 342 patients of CEAP 6 with manifestations of chronic vein insufficiency on the background of varicose disease (VD) and post-thrombotic syndrome (PTS) in the surgical clinic of the Transcarpathian Regional Clinical Hospital named after A. Novak (Uzhhorod) for the last 10 years. At least 169 patients had VD (CEAP 6). Post-thrombotic syndrome (occlusive form) was observed in 173 patients (CEAP 6). The ratio of women to men in VD was 3:1, and in PTS was 3:2.

Results. In patients of group I (crossectomy + short stripping + distal scleroobliteration), postoperative complications developed in only 2 (4.3 %) patients in the form of suppuration of the operative wound on the thigh and lymphorrhea. With extended venectomy + SEPS, early postoperative complications were observed in 5 (6 %) patients: three patients had suppuration of the postoperative wound on the thigh, and two patients had lymphorrhea. In classical venectomy + Linton's operation, inguinal wound suppuration occurred in 2 (5.3 %), lymphorrhea in 3 (7.9 %) patients. Suppuration of the postoperative wound on the lower leg was observed in another 3 (7.9 %) patients. The long-term outcomes in the patients of the group I were: 9 (19.1 %) patients had partial recanalization of the perforated veins of the group of great saphenous vein (GSV) on the lower leg, and one (2.1 %) had complete recanalization. Trophic ulcer (TU) did not heal in one patient after conservative treatment, relapse of TU occurred in 7 (4.1 %) patients. In patients of the group II thrombosis of the cross autovenous shunt (during Palma's operation) in the early postoperative period was observed in 5 (8.5 %) patients, during autovenous shunting and Husni's operation (transposition of the GSV into the popliteal vein) in no case. During Linton's operation, suppuration of the postoperative wound was observed in 7 (15.9 %) cases. TU did not heal with conservative treatment in 5 (56 %) patients.

Conclusions. In the stage of decompensation of VD, pathogenetically justified treatment is crossectomy, venectomy with elimination of horizontal reflux in the zone of trophic ulcer. Trophic ulcers <5 cm and >2 cm deep I–II degrees are treated conservatively after surgery and heal independently within a year. Phlebectomy and CE of the affected limb are contraindicated in PTS. Pathogenetically justified method of treatment is reconstructive and restorative surgery to restore main blood flow with elimination of horizontal reflux in the zone of trophic ulcer.

Modern medical technology. 2024;(1):32-39

Вибір методу хірургічної корекції залежно від етіології декомпенсованої хронічної венозної недостатності

В. І. Русин, Ф. М. Павук, В. В. Русин, М. І. Борсенко

Мета роботи – оцінити найближчі та віддалені результати лікування залежно від етіології хронічної венозної недостатності в стадії декомпенсації.

Матеріали і методи. Проаналізували результати лікування 342 хворих із CEAP 6, проявами хронічної венозної недостатності (ХВН) на тлі варикозної хвороби (ВХ) та посттромботичного синдрому (ПТС) у хірургічній клініці КНП «Закарпатська обласна клінічна лікарня імені Андрія Новака» ЗОР (м. Ужгород) за останні 10 років. ВХ (CEAP 6) діагностували в 169 пацієнтів, посттромботичний синдром (оклюзивна форма) – в 173 осіб (CEAP 6). Співвідношення жінок і чоловіків із ВХ становило 3:1, а з ПТС – 3:2.

Результати. У хворих I групи (кроссектомія + короткий стріпінг + дистальна склерооблітерація) післяопераційні ускладнення виникли лише у 2 (4,3 %) випадках, зокрема діагностували нагноєння операційної рани на стегні та лімфорею. При розширеній венектомії у поєднанні з SEPS ранні післяопераційні ускладнення визначили у 5 (6 %) хворих, у трьох пацієнтів – нагноєння післяопераційної рани на стегні, у двох – лімфорею. При класичній венектомії в поєднанні з операцією Лінтона нагноєння пахової рани зафіксували у 2 (5,3 %), лімфорею – у 3 (7,9 %) пацієнтів. Ще у 3 (7,9 %) хворих виникло нагноєння післяопераційної

рани на гомілці. У віддаленому періоді спостереження серед пацієнтів першої групи у 9 (19,1 %) осіб виявили часткову реканалізацію перфорантних вен у басейні великої підшкірної вени (ВПВ) на гомілці, в одного (2,1 %) – повну реканалізацію. Трофічна виразка (ТВ) після консервативного лікування не загоїлася в одного хворого, рецидив ТВ виник у 7 (4,1 %) пацієнтів. У хворих другої групи тромбоз перехресного аутовенозного шунта (при операції Пальми) в ранньому післяопераційному періоді виявили у 5 (8,5 %) випадках, при аутовенозному шунтуванні та операції Гусні (транспозиція ВПВ у підколінну вену) – не зафіксовано. Під час операції Лінтона нагноєння післяопераційної рани виникло у 7 (15,9 %) випадках. У 5 (56 %) хворих ТВ не вилікували консервативно.

Висновки. У стадії декомпенсації ВХ патогенетично обґрунтованим лікуванням є кросектомія, венектомія з усуненням горизонтального рефлюксу в зоні трофічної виразки. Трофічні виразки <5 см і >2 см із глибиною I–II ступенів після операції лікують консервативно; вони загоюються самостійно протягом року. При ПТС протипоказані флебектомія і кросектомія ураженої кінцівки. Патогенетично обґрунтованим методом лікування є реконструктивно-відновні операції для відновлення магістрального кровотоку з усуненням горизонтального рефлюксу в зоні трофічної виразки.

Сучасні медичні технології. 2024. № 1(60). С. 32-39

The main reasons for trophic ulcers development in the patients with chronic venous insufficiency are the formation of persistent pathological vertical reflux in the deep and superficial venous system, as well as the presence of horizontal reflux at the level of the communicating and perforating veins of the lower third of the thigh and lower leg [1,2,3,4]. Orthostatic phlebostasis provokes progression of venous hemodynamic disorder and causes deterioration of microcirculation with impaired tissue trophism [5,6,7,8]. Based on these provisions, the basic principles of pathogenetically-induced treatment of trophic ulcers are formed. The most important of them are:

- 1) surgical treatment (sclerosing, venectomy, autovenous shunting, correction of valvular insufficiency);
- 2) compression therapy;
- 3) medical treatment (venotonics, disaggregants, antihistamines, anti-inflammatory drugs, systemic antibiotic therapy);
- 4) local treatment of ulcers before spontaneous epithelization or before dermatoplasty (surgical cleaning of the wound (VAC or Maggot therapy), sanitation, washing, medical bandages);
- 5) rehabilitation (further care, compliance with the work and rest regime, restriction of staying in an upright and sitting position, cosmetic products and phlebotonics, dispensation).

The algorithm of surgical treatment of patients with lower limb deep vein valve insufficiency includes several stages: removal of varicose veins of the subcutaneous veins, elimination of horizontal reflux by echoscleroobliteration of perforating veins and/or subfascial ligation of failed perforating veins (Linton's operation) and/or subfascial endoscopic perforator surgery (SEPS), correction of the venous valve closure function of the common femoral vein. In the modern literature there is very little information about

the correction of the valvular apparatus, and if it appears, it is somehow veiled, since it is almost impossible to evaluate the results of such interventions against the background of complex treatment of chronic vein insufficiency (CVI), and there are only characteristics of the used treatment methods that do not have quantitative characteristics.

Aim

To evaluate the immediate and distant results of treatment depending on the etiology of chronic venous insufficiency in the stage of decompensation.

Materials and methods

This work presents an analysis of the results of treatment of 342 patients of CEAP 6 with manifestations of CVI on the background of varicose disease (VD) and post-thrombotic syndrome (PTS) in the surgical clinic of the Transcarpathian Regional Clinical Hospital named after A. Novak (Uzhhorod) for the last 10 years. 169 patients had VD (CEAP 6). PTS (occlusive form) was observed in 173 patients (CEAP 6). The ratio of women to men in VD was 3:1, and in PTS was 3:2.

Trophic ulcers (TU) of small size were observed in 57 (33.7 %) patients of group I, medium size – in 71 (42 %) patients, where the depth of the lesion was II degree. Only in 41 (24.3 %) patients, the TU area exceeded 100 cm² at the III degree of lesion depth (Table 1). In the group II, small TU were observed in 5.2 %, medium size in 44.0 % at the II degree of lesion depth, and large size in 50.3 % at the III degree of lesion depth, and only one patient had the IV degree of lesion depth.

Table 1. TU planimetry depending on the etiopathogenesis of CVI

Diameter of trophic ulcer, cm	I group, n = 169	Depth of trophic ulcer, degree	II group, n = 173	Depth of trophic ulcer, degree
>2 – <5	57 (33.7 %)	II	9 (5.2 %)	II
>5 – <10	71 (42.0 %)	II	76 (44.0 %)	II
>10	41 (24.3 %)	III	87 (50.3 %)	III
	–	IV	1 (0.5 %)	IV

Table 2. Types and number of operations for CVI depending on the etiology of the disease

Stage of venous insufficiency	The name of the operation	n
C6	VD, n = 169	
	Crossectomy (CE) – venectomy + SEPS	83
	CE – short stripping, distal scleroobliteration	47
	CE – venectomy + Linton's operation	32
	CE venectomy paravasal compression of the femoral vein valve	7
	Autodermoplasty	112
	PTS, n = 173	
	Palma's operation	69
	Autovenous bypass	7
	Husni's operation	6
	Paravasal compression of the femoral vein valve Echoscleroobliteration of penetrating veins	7
	Linton's operation	44
	Echoscleroobliteration of penetrating veins	50
	Autodermoplasty	164

Table 3. Criteria for evaluating the long-term results of treatment of CVI

The results	An increase in the length of the surrounding limb (increasing edema)	Increase in induration area	Fatigue	Trophic ulcers	Shunt patency
Distinctive	2 cm	–	–	–	+
Good	3 cm	–	+	–	+
Satisfactory a)	4 cm*	–	++	–	–
Satisfactory b)	<4 cm	–	++	+	–
Unsatisfactory	>4 cm	+	+++	+	–

*: swelling of the lower leg only in the absence of swelling on the thigh; +: fatigue in the evening; ++: fatigue during physical exertion; +++: fatigue with minor physical exertion.

Evaluation of the lesion depth according to Fital classification:

- I degree of damage depth to the dermis;
- II degree – dermis, subcutaneous tissue and/or fibrous tissue;
- III degree – muscles, tendons, and vascular-nerve bundles;
- IV degree – bone and joint structures.

The types and number of operations for CVI in the stage of decompensation, depending on the etiology of the disease, are presented in the *Table 2*.

In the case of VD, CE, venectomy, distal scleroobliteration, ligation of failed perforants in one way or another prevailed. In case of PTS, CE with venoextraction was practically not used, while reconstructive and restorative operations and elimination of horizontal reflux by scleroobliteration and subfascial ligation of perforating veins were performed.

Extravasal compression of the valvular apparatus of the femoral vein was used alone in 7 cases of VD and PTS.

In group I of 169 patients, trophic ulcers were cleaned with the help of VAC therapy in 71 patients, Magott therapy was used in 41 patients. In group II of 173 patients, VAC therapy was used in 16, and Magott therapy in 164 patients, 27 of them on both limbs (54 patients).

Conservative treatment of small superficial TU (up to 10 cm²) was used in 57 patients of group I and 9 patients of group II. Dermatoplasty by metric method was used in 32 patients of group I and 2 patients of group II. Split skin graft transplantation was used in 39 patients of the I group and 74 patients of group II. Transplantation of a split perforated skin graft was performed in 41 patients of group I and 87 patients of group II (a total of 114 limbs).

Free transplantation of a complex of tissues was performed in one patient of group II.

When evaluating the results of treatment, the following criteria were considered: edema, increase in the induration area, fatigue, trophic ulcers, patency of shunts (*Table 3*).

Table 4. Treatment results depending on the etiology of the disease

Venous insufficiency	Etiology			
	Varicose veins		Post-thrombotic syndrome	
	Direct results	In a year	Direct results	In a year
	C6	91.7 %	89.4 %	90.2 %
	Dermatoplasty			
	98.25 %	93.75 %	97.1 %	91.3 %

Results

Immediate and long-term results differ, and this is most noticeable depending on the etiology of the disease (Table 4).

In patients of group I (CE + short stripping + distal scleroobliteration), postoperative complications developed in only 2 (4.3 %) patients in the form of suppuration of the operative wound on the thigh and lymphorrhea. With extended venectomy + SEPS, early postoperative complications were observed in 5 (6 %) patients: three patients had suppuration of the postoperative wound on the thigh and two patients had lymphorrhea. Marginal necrosis of the wound in the upper third of the lower leg at the endoscope insertion site was noted in two (2.4 %) patients.

In classical venectomy + Linton's operation, inguinal wound suppuration occurred in 2 (5.3 %), lymphorrhea in 3 (7.9 %) patients. Suppuration of the postoperative wound on the lower leg was observed in another 3 (7.9 %) patients.

The long-term outcomes (1 year), among the patients of group I were: 9 (19.1 %) patients had partial recanalization of perforated veins of the group of great saphenous vein (GSV) on the lower leg, and one (2.1 %) had complete recanalization. TU did not heal in one patient after conservative treatment, relapse of TU occurred in 7 (4.1 %) patients.

In patients of group II, thrombosis of the cross autovenous shunt during Palma's operation in the early postoperative period was observed in 5 (8.5 %) patients, during autovenous shunting and Husni's operation (transposition of the GSV into the popliteal vein) – in no case. During Linton's operation, suppuration of the postoperative wound was observed in 7 (15.9 %) cases. TU did not heal with conservative treatment in 5 (56 %) patients.

The long-term outcomes (1 year), shunt thrombosis after Palma operation accounted for 13 (22 %) cases. It is most difficult to interpret the result of treatment in PTS against the background of inferior vena cava syndrome or the consequences of bilateral iliofemoral thrombosis.

In linear shunt operations, shunt thrombosis was not observed. With echoscleroobliteration of penetrating veins, recanalization occurred in 15 (30 %) cases, TU recurrence in 15 (8.7 %).

Regardless of the etiology of CVI in the stage of decompensation, excellent treatment results were not observed. In the case of VD in the stage of decompensation, a good and satisfactory result was observed in 91.7 %, and in the immediate PTS, a good and satisfactory result was only in 87.7 % of patients.

At the same time, we are convinced that the interpretation of the patency of shunt operations in patients with PTS of femoral-iliac localization is not entirely correct. Since in a number of cases,

with thrombosis of shunts, we observed a good and satisfactory clinical condition of the affected limb, and vice versa – in a number of cases, with good function of shunts, we observed pronounced swelling of the leg with trophic disorders.

Satisfactory results of dermatoplasty in group I were observed in 98.3 % of patients and in group II in 97.1 % of cases. In 27 patients, PTS of both lower extremities was present in 95 % of cases.

At the same time, most of the unsatisfactory results of autodermatoplasty were related to technical reasons and were observed when the vintage method of the latter was used. The best results were achieved with plastic surgery with a perforated split flap. After a year, the healing rate of TU in VD was 97.1 %, and in PTS 91.3 %.

Discussion

Varicose veins of the lower extremities begin from the saphenous femoral confluence (SFC) or sapheno-popliteal confluence (SPC) and extremely rarely from penetrating and communicating veins [7,9,10,11].

The group of authors (Catarinella F., 2014) report that after 1 year in patients with decompensated forms of chronic venous insufficiency of PTS etiology, the healing rate of TU is about 70 % with the use of venous stenting. In our study, good healing results of trophic ulcers in patients with PTS were observed in 83.2 % of cases without the use of dermatoplasty. According to the authors [17], good results were observed only in 87 % of VD (CEAP 6) cases. Evaluating the results of treatment of patients with a decompensated form of VD, good results were observed in 89.4 % of cases after 1 year. When using hybrid surgery (stenting + AV fistula + endophlebectomy) in the treatment of a complicated form of PTS, the results in the group of authors (T. M. A. J. van Vuuren; M. Dumantepe) after 1 year range from 64 % to 90 % of good results, and in decompensated forms of VD this indicator is 90–100 % [18,19]. The incidence of thrombosis ranges from 5.3 % to 18.3 % [4,5,6,7,8,12,18]. In our work the long-term outcomes (1 year), shunt thrombosis (after Palma operation) accounted for 13 (22 %) cases. In linear shunt operations, shunt thrombosis was not observed.

In our research 9 (19.1 %) patients of group I had partial recanalization of the perforated veins of the group of great saphenous vein GSV on the lower leg, and one (2.1 %) had complete recanalization while in the study of other authors the percent of recanalization is at the level of 15–25 % [10,11,12,13,14,17]. TU did not heal in one patient after conservative treatment, relapse of TU occurred in 7 (4.1 %) patients. On the other hand, some scientists report that after conservative treatment bad results

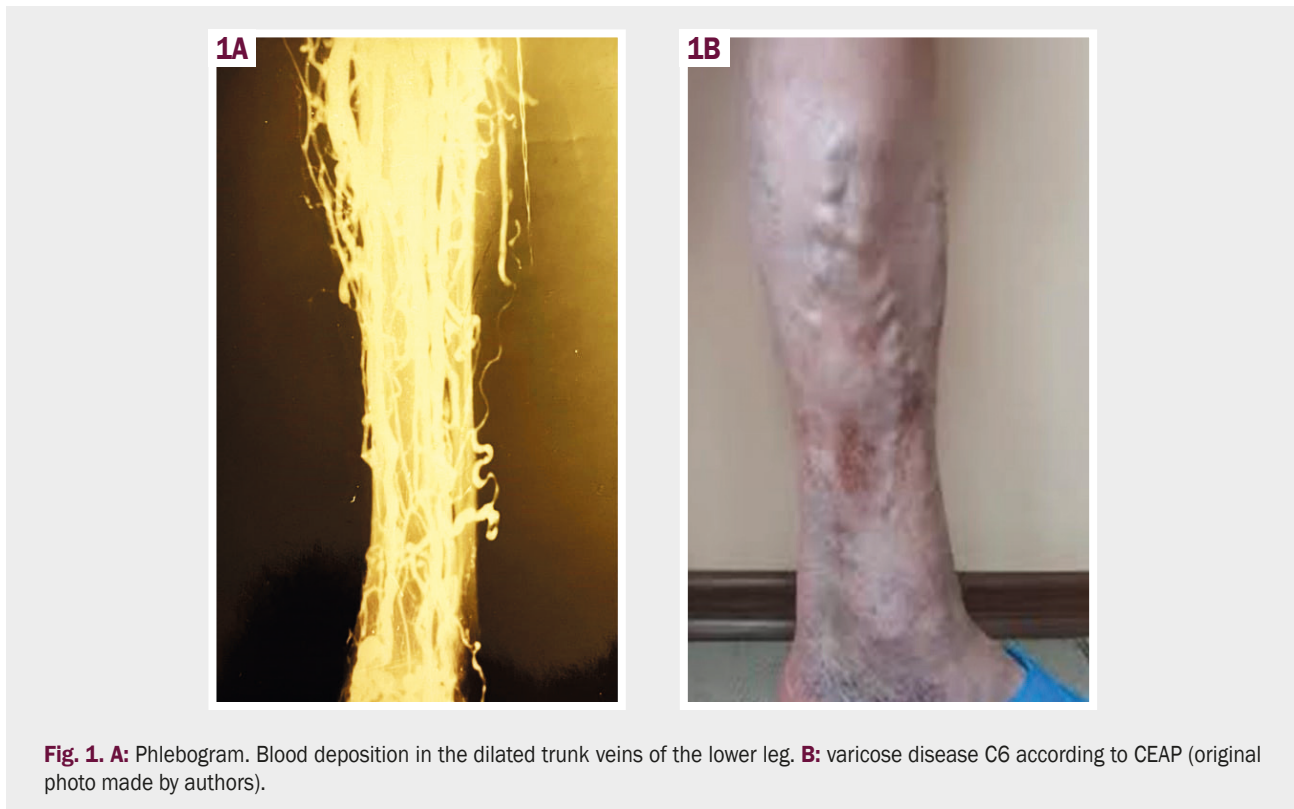

Fig. 1. A: Phlebogram. Blood deposition in the dilated trunk veins of the lower leg. **B:** varicose disease C6 according to CEAP (original photo made by authors).

occurred in 5–10 % patients with C6 TU with VD and almost in 35–40 % patients with PTS [1,2,3,4,5,15,16,17,18].

Although experts associate the beginning of varicose transformation with the expansion of individual tributary venous branches, and the failure of the main trunks develops much later. This theory is the basis of organ-sparing methods of treatment of VD (ASVAL) [12,13,14]. Insufficiency of permeating veins appears as pathological venous capacity increases in superficial veins and is characterized by damage to one or two incompetent perforating veins on the lower leg. Under the influence of increased blood flow from the superficial venous network, deep veins may dilate segmentally, with the trunk veins of the lower leg dilating first (Fig. 1).

In these conditions, the main compensatory role is assigned to the small saphenous vein (SSV), including due to the deposition of blood in intramuscular collectors [11,15]. The deposition of blood in the saccular veins leads to overload and inefficient work of the SSV, and pathological hypervolemia leads to an increase in the number of failed veins associated with the SSV of the lower leg. With complete dysfunction of the SSV, supraosseous perforating veins are involved in the pathological process, which are considered as a typical cause of trophic disorders development [16].

It is interesting that, according to modern ideas, the failure of perforating veins is considered to be reversed after the elimination of reflux from the superficial venous network [16].

In our material, at CEAP 6, only 19 % of patients underwent an operation on perforating veins along with venectomy and crosssectomy.

Despite the fact that there are reports in the special literature that CVI develops in approximately half of patients after deep vein thrombosis, in practice venous insufficiency is almost

always observed to some degree or another. That is why deep vein thrombosis (DVT) can be characterized as an irreversible process where its treatment without significant consequences is rather an exception, as a rule [4,5,6,12].

From the point of view of a practical doctor, the following forms of PTS are distinguished: occlusive, mixed and recanalized. With deep vein thrombosis, there is an overload of the SSV due to the deposition of blood on the lower leg associated with the absence of outflow pathways, but there is still no pathological blood flow. At the second stage, a pathological directionality of blood flow occurs due to the occurrence of horizontal reflux. The third stage is an increase in retrograde blood flow due to incompetent penetrating veins, even in the case of recanalization of the thrombosed venous segment.

In our practical work, we divide the venous system of the lower extremities into four segments: tibio-popliteal, popliteal-femoral, femoral-iliac and ilio-caval segments. By the term venous segment, we understand the totality of all vessels carrying centripetal blood flow. The following are involved in the formation of the segment: the afferent trunk veins of the leg, the proximal part of the saphenous vein, the femoral vein, the external iliac vein, the inferior vena cava, venous collectors (there are four of them: popliteal, femoral, iliac, caval) and their shunts (small and large subcutaneous veins, deep femoral vein, genital, intrailiac, vertebral veins and ascending lumbar vein), as well as external trunks (common femoral, external iliac, inferior vena cava). One and the same vessel can be profitable for one and removable for another segment (Fig. 2).

Each collector has a bypass – a natural shunt, the degree of outflow disturbance depends on its functionality. For the popliteal, these are SSV, GSV, DFV and collaterals – network of the knee

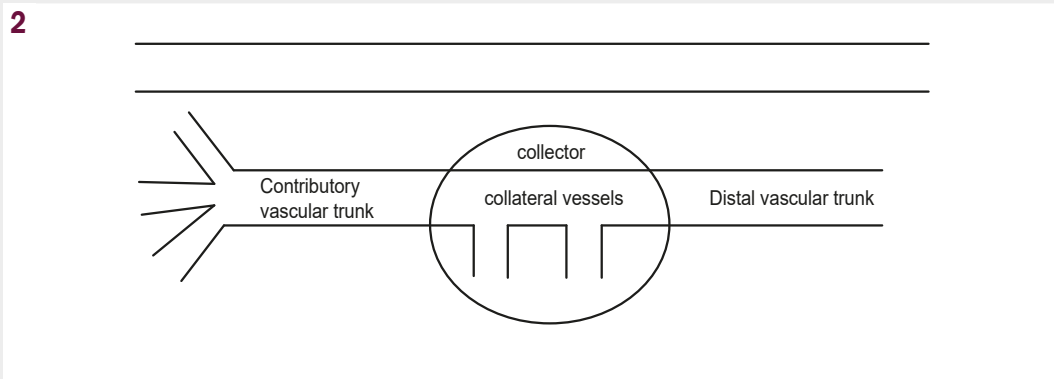


Fig. 2. Scheme of the structure of the venous collector (authors' drawing).

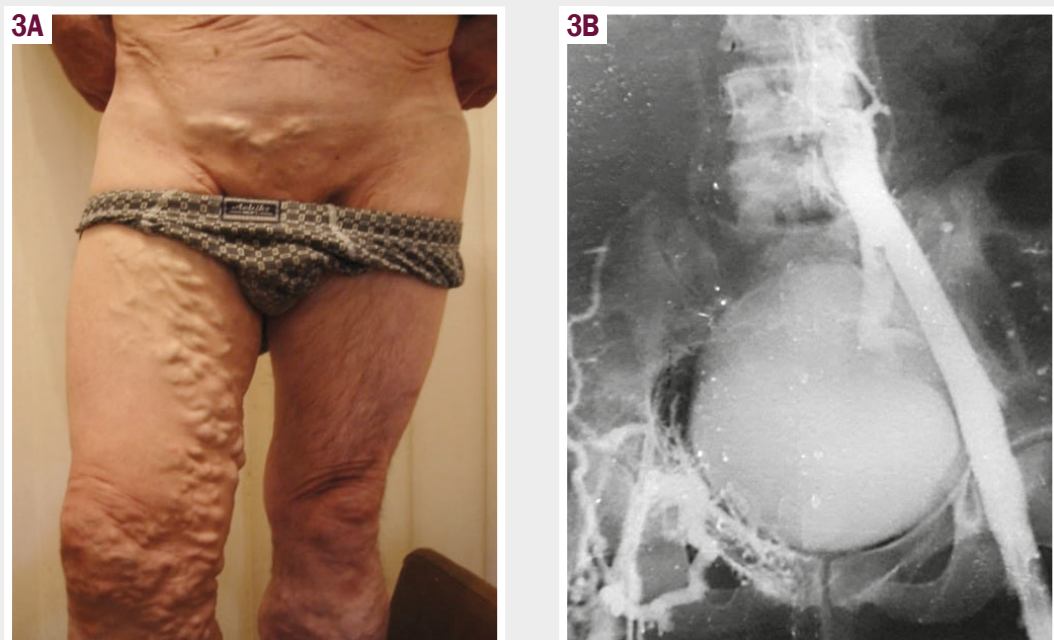

Fig. 3. A: PTS of the right lower extremity with varicose veins of the subcutaneous veins of the lower extremity and anterior abdominal wall. **B:** Phlebogram. Occlusion of the femoral-iliac and ilio-caval segments on the right (original photo made by authors).

joint, vein of Leonardo, Giacomini; for the femoral collector is the femoral vein and the sacral plexus; for iliac – internal iliac veins and veins of the anterior abdominal wall; for the iliac – azygos and semi azygos veins, lumbar veins and their venous plexuses, intervertebral and lower diaphragmatic veins, hepatic, gonadal veins and venous plexuses of the pelvis.

Coming out of the collector, there is always a trunk that does not have a large number of tributaries, in particular, the femoral vein, common femoral vein (CFV), common iliac vein and inferior vena cava. At the same time, the main shunt for thrombosis of the CFV and femoral vein is the GSV, which is able to supply up to 85 % of the limb, in addition, the deep and encircling femoral veins are of great importance in blood flow compensation.

A distinctive feature of decompensated forms of PTS is retrograde blood flow through the main veins at the level of the sural part of the leg with the involvement of valveless perforating veins and the creation of zones of venous stasis (hypertension) in the periosteal and subosteal areas. In this way, a “vicious

circle” is formed, which cannot always be broken by eliminating the reflux in the main veins of the distal leg. Obviously, for this reason, in the remote postoperative period, satisfactory and good results after isolated Linton surgery were observed only in 88 % of patients.

The possible option for surgical treatment is the occlusion of the common tibial vein (CTV) according to Vedensky and SEPS. However, the limitation of the latter is the periosteal area of the lower leg, and remote occlusion of the CTV carries the risk of ascending deep vein thrombosis.

The next level of possible help is the popliteal vein and the distal part of the femoral vein. But in the literature available to us, it was not possible to find modern data on the transposition or formation of an artificial valve at this level with satisfactory results in the remote observation period. In our report, linear autovenous shunts gave a satisfactory result after one year of observation in 100 % of cases, while cross-over autovenous shunting (Palma operation) gave a positive result only in 78 % of cases, that is

obviously related to errors during the selection of patients for such an intervention.

And it is not entirely correct to evaluate the results of extravasation compression of the femoral vein valve in these patients because echosclerobliteration of perforating veins was performed in parallel.

Despite the similarity of the external signs of lesions in VD and PTS, signs of valvular failure of superficial veins in PTS are milder than in VD. The mechanism of their failure is related to the redistribution of blood from the deep venous system through the failed perforating veins to the superficial (Fig. 3).

And in such a situation, the question arises as to how outflow from the affected lower extremity will occur if varicose and dilated subcutaneous veins are removed. There is no doubt that in a specific case, reconstructive and restorative surgery (autovenous shunting and/or prosthetics) of the femoral-caval segment is pathogenetically more justified.

In the discussion of the obtained results, it is necessary to highlight several points. Trophic disorders in VD depend more on vertical reflux in the superficial venous system with the formation of hypervolemia in the system of deep veins of the lower leg. Trophic disorders in PTS primarily depend on the severity of deep vertical reflux. Intense retrograde blood flow through failed perforating veins causes severe structural changes in the venous wall, as in VD, so there is no need to count on the restoration of the function of perforating veins after surgical treatment. The damaging effect of vertical deep reflux is realized in PTS due to incompetent perforating veins, which justifies their ligation (bandaging).

The choice of operative treatment method depends on the localization of primary deep vein thrombosis (tibial-popliteal, popliteal-femoral, femoral-iliac, ilio-caval segment) and its form – occlusive, recanalization.

In the case of damage to the I–II segments of the PTS, as a treatment option, the transposition of the GSV in the popliteal vein, below the site of occlusion, extravasation correction in the third and/or lower part of the femoral vein with the aim of correcting vertical deep reflux is suggested. Elimination of horizontal reflux is one of the available methods.

With III–IV segments of PTS lesions and its occlusive forms, local outflow restoration from the lower extremity is possible at the expense of Palm surgery or autovenous bypass shunting and/or prosthetics with a satisfactory observation result in 78 % of cases within a year. In case of trophic ulcers of the lower leg, echosclerotic obliteration of inoperable perforating veins is mandatory.

Conclusions

1. In the stage of decompensation of VD, pathogenetically justified treatment is cross-section, venectomy with elimination of horizontal reflux in the zone of trophic ulcer. Trophic ulcers <5 cm and >2 cm deep I–II degrees are treated conservatively after surgery and heal independently within a year.

2. Phlebectomy and CE of the affected limb are contraindicated in PTS. Pathogenetically justified method of treatment is reconstructive and restorative surgery group to restore main blood

flow with elimination of horizontal reflux in the zone of trophic ulcer.

3. Medium-sized and large trophic ulcers of varicose origin or PTS require autodermoplasty with a split perforated skin flap, after cleaning the recipient bed with VAC or Magott therapy.

Information about authors:

Rusyn V. I., MD, PhD, DSc, Professor of the Department of Surgical Diseases, State University "Uzhhorod National University", Ukraine.

ORCID ID: 0000-0001-5688-9951

Pavuk F. M., MD, PhD, Assistant of the Department of Oncology, State University "Uzhhorod National University", Ukraine.

ORCID ID: 0000-0001-6721-9806

Rusyn V. V., MD, PhD, DSc, Professor of the Department of Oncology, State University "Uzhhorod National University", Ukraine.

ORCID ID: 0000-0003-4854-0228

Borsenko M. I., MD, PhD, Radiologist (Ultrasound), Surgeon of Transcarpathian Regional Clinical Hospital named after A. Novak, Uzhhorod, Ukraine.

ORCID ID: 0009-0006-1607-5906

Відомості про авторів:

Русин В. І., д-р мед. наук, професор каф. хірургічних хвороб, ДВНЗ «Ужгородський національний університет»; КНП «Закарпатська обласна клінічна лікарня імені Андрія Новака» ЗОР, м. Ужгород, Україна, лауреат Державної премії України в галузі науки і техніки, заслужений лікар України.

Павук Ф. М., канд. мед. наук, асистент каф. онкології, ДВНЗ «Ужгородський національний університет», Україна.

Русин В. В., д-р мед. наук, професор каф. хірургічних хвороб, ДВНЗ «Ужгородський національний університет», Україна.

Борсенко М. І., канд. мед. наук, лікар ультразвукової діагностики, КНП «Закарпатська обласна клінічна лікарня імені Андрія Новака» ЗОР, м. Ужгород, Україна.

References

1. Åström H, Blomgren L. Does eradication of superficial vein incompetence after superficial vein thrombosis reduce the risk of recurrence and of deep vein thrombosis? A pilot study evaluating clinical practice in Örebro county, Sweden. *Phlebology*. 2022;37(8):610-5. doi: [10.1177/02683555221113402](https://doi.org/10.1177/02683555221113402)
2. Bergan JJ, Bunke N, editors. *The vein book*. Oxford University Press, USA; 2014.
3. Bradbury AW. Epidemiology and aetiology of C4–6 disease. *Phlebology*. 2010;25(1 suppl):2-8. doi: [10.1258/phleb.2010.010s01](https://doi.org/10.1258/phleb.2010.010s01)
4. Budd TW, Meenaghan MA, Wirth J, Taheri SA. Histopathology of veins and venous valves of patients with venous insufficiency syndrome: ultrastructure. *J Med*. 1990;21(3-4):181-99.
5. Galanaud JP, Genty C, Sevestre MA, Brisot D, Lausecker M, Gillet JL, et al. Predictive factors for concurrent deep-vein thrombosis and symptomatic venous thromboembolic recurrence in case of superficial venous thrombosis. The OPTIMEV study. *Thromb Haemost*. 2011;105(1):31-9. doi: [10.1160/TH10-06-0406](https://doi.org/10.1160/TH10-06-0406)
6. Gloviczki P, editor. *Handbook of venous disorders: Guidelines of the American venous forum third edition*. CRC Press; 2008.
7. Hamdan A. Management of varicose veins and venous insufficiency. *Jama*. 2012;308(24):2612-21. doi: [10.1001/jama.2012.111352](https://doi.org/10.1001/jama.2012.111352)
8. Labropoulos N, Delis K, Nicolaidis AN, Leon M, Ramaswami G, Volteas N. The role of the distribution and anatomic extent of reflux in the development of signs and symptoms in chronic venous insufficiency. *J Vasc Surg*. 1996;23(3):504-10. doi: [10.1016/S0741-5214\(96\)80018-8](https://doi.org/10.1016/S0741-5214(96)80018-8)
9. Lee SH, Kim WH. Superficial Vein Thrombosis and Severe Varicose Veins Complicating Venous Thromboembolism. *J Cardiovasc Imaging*. 2019;27(2):154-5. doi: [10.4250/jcvi.2019.27.e14](https://doi.org/10.4250/jcvi.2019.27.e14)
10. Lim CS, Davies AH. Pathogenesis of primary varicose veins. *Br J Surg*. 2009;96(11):1231-42. doi: [10.1002/bjs.6798](https://doi.org/10.1002/bjs.6798)
11. Lim CS, Kiriakidis S, Paleolog EM, Davies AH. Increased activation of the hypoxia-inducible factor pathway in varicose veins. *J Vasc Surg*. 2012;55(5):1427-39. doi: [10.1016/j.jvs.2011.10.111](https://doi.org/10.1016/j.jvs.2011.10.111)

12. Litzendorf ME, Satiani B. Superficial venous thrombosis: disease progression and evolving treatment approaches. *Vasc Health Risk Manag.* 2011;31:569-75. doi: <http://dx.doi.org/10.2147/VHRM.S15562>
13. Sansilvestri-Morel P, Rupin A, Badier-Commander C, Kern P, Fabiani JN, Verbeuren TJ, et al. Imbalance in the synthesis of collagen type I and collagen type III in smooth muscle cells derived from human varicose veins. *J Vasc Res.* 2001;38(6):560-8. doi: [10.1159/000051092](https://doi.org/10.1159/000051092)
14. Sidawy AP, Perler AP. *Rutherford's Vascular Surgery and Endovascular Therapy, 2-Volume Set.* S.L.: Elsevier – Health Science; 2022.
15. Tauraginskii RA, Lurie F, Simakov S, Borsuk D, Mazayshvili K. Gravity force is not a sole explanation of reflux flow in incompetent great saphenous vein. *J Vasc Surg Venous Lymphat Disord.* 2019;7(5):693-8. doi: [10.1016/j.jvsv.2019.04.012](https://doi.org/10.1016/j.jvsv.2019.04.012)
16. Wali MA, Eid RA. Intimal changes in varicose veins: an ultrastructural study. *J Smooth Muscle Res.* 2002;38(3):63-74. doi: [10.1540/jsmr.38.63](https://doi.org/10.1540/jsmr.38.63)
17. Catarinella F, Nieman F, de Wolf M, Wittens C. Short-term follow-up of Quality-of-Life in interventional treated patients with post-thrombotic syndrome after deep venous occlusion. *Phlebology.* 2014;29(1 suppl):104-11. doi: [10.1177/0268355514529505](https://doi.org/10.1177/0268355514529505)
18. van Vuuren TMAJ, de Wolf MAF, Arnoldussen CWKP, Kurstjens RLM, van Laanen JHH, Jalaie H, et al. Editor's Choice – Reconstruction of the femoro-ilio-caval outflow by percutaneous and hybrid interventions in symptomatic deep venous obstruction. *Eur J Vasc Endovasc Surg.* 2017;54(4):495-503. doi: [10.1016/j.ejvs.2017.06.023](https://doi.org/10.1016/j.ejvs.2017.06.023)
19. Dumantepe M, Aydin S, Ökten M, Karabulut H. Endophlebectomy of the common femoral vein and endovascular iliac vein recanalization for chronic iliofemoral venous occlusion. *J Vasc Surg Venous Lymphat Disord.* 2020;8(4):572-82. doi: [10.1016/j.jvsv.2019.11.008](https://doi.org/10.1016/j.jvsv.2019.11.008)